

Pediatric Pulmonary Edema / CHF



History

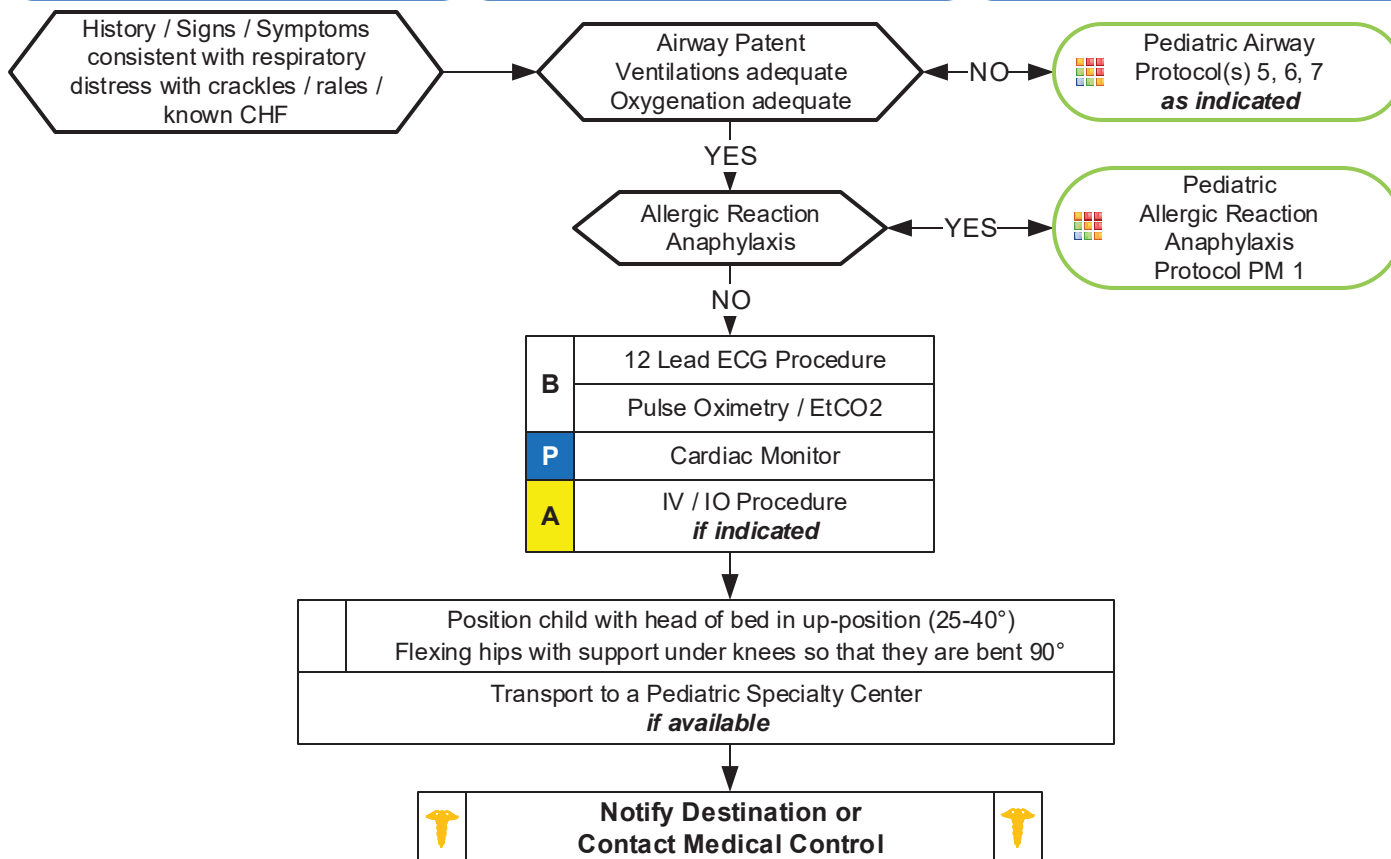
- Congenital Heart Disease
- Chronic Lung Disease
- Congestive heart failure
- Past medical history

Signs/Symptoms

- Infant: Respiratory distress, poor feeding, lethargy, weight gain, +/- cyanosis
- Child/Adolescent: Respiratory distress, bilateral rales, apprehension, orthopnea, jugular vein distention (rare), pink, frothy sputum, peripheral edema, diaphoresis, chest pain
- Hypotension, shock

Differential

- Congestive heart failure
- Asthma
- Anaphylaxis
- Aspiration
- Pleural effusion
- Pneumonia
- Pulmonary embolus
- Pericardial tamponade
- Toxic Exposure



Pearls

- **Recommended exam: Mental status, Respiratory, Cardiac, Skin, Neuro**
- **Contact Medical Control early in the care of the pediatric cardiac patient.**
- **Most children with CHF have a congenital heart defect, obtain a precise past medical history.**
- **Congenital heart disease varies by age:**
 - < 1 month: Tetralogy of Fallot, Transposition of the great arteries, Coarctation of the aorta.
 - 2 – 6 months: Ventricular septal defects (VSD), Atrioseptal defects (ASD).
 - Any age: Myocarditis, Pericarditis, SVT, heart blocks.
- **Treatment of Congestive Heart Failure / Pulmonary edema may vary depending on the underlying cause and may include the following with consultation by Medical Control:**
 - Morphine Sulfate: 0.1 mg/kg IV / IO. Max single dose 5mg/dose
 - Fentanyl: 1 mcg/kg IV / IO. Max single dose 50 mcg.
 - Nitroglycerin: Dose determined after consultation of Medical Control.
 - Lasix 1 mg/kg IV / IO.
 - Agency specific vasopressor.
- Do not assume all wheezing is pulmonary, especially in a cardiac child: avoid albuterol unless strong history of recurrent wheezing secondary to pulmonary etiology (discuss with Medical Control)