



PEDIATRIC TACHYCARDIA

WIDE COMPLEX (> 0.09 SEC)

History

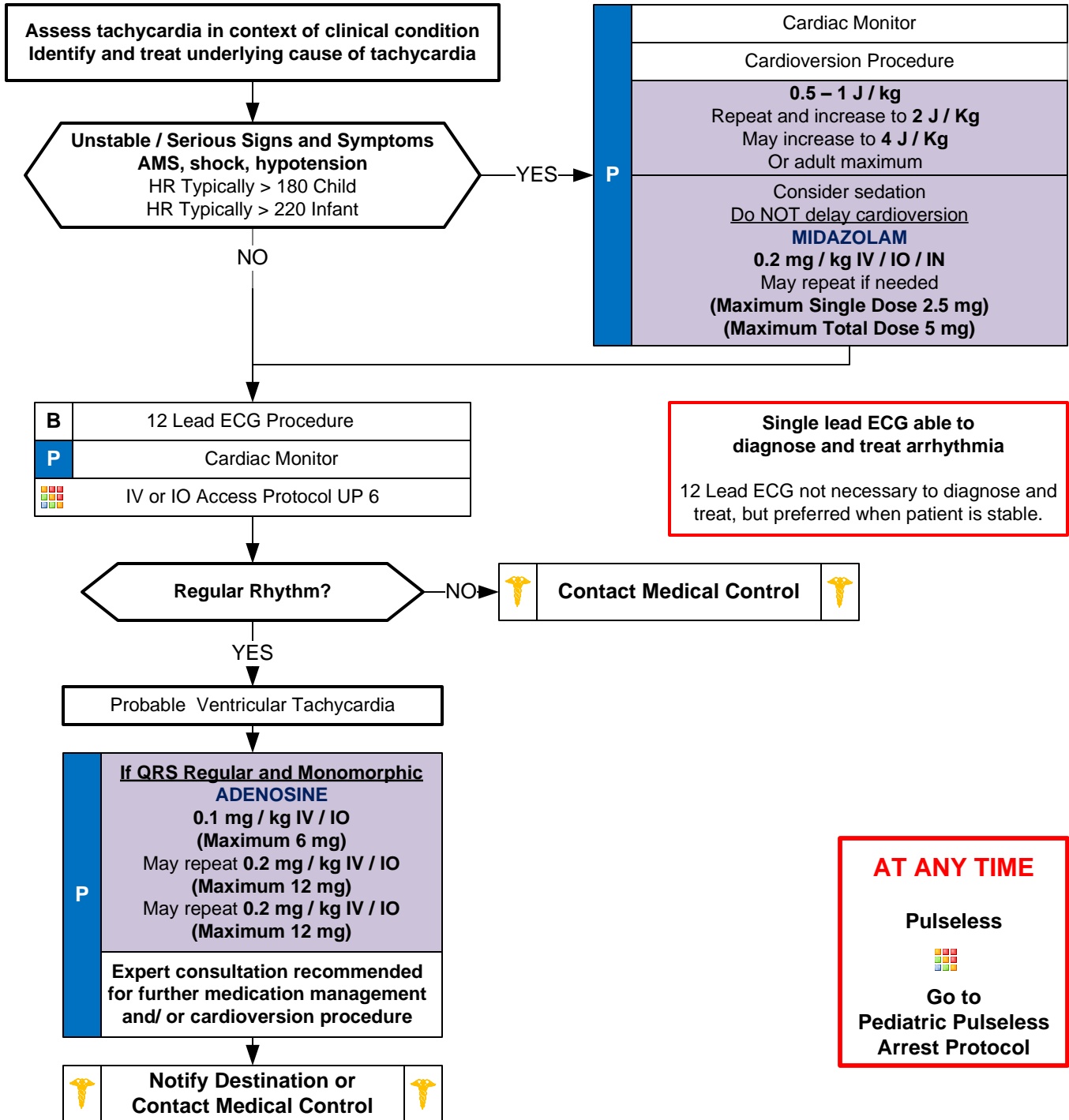
- Past medical history
- Medications or Toxic Ingestion (Aminophylline, Diet pills, Thyroid supplements, Decongestants, Digoxin)
- Drugs (nicotine, cocaine)
- Congenital Heart Disease
- Respiratory Distress
- Syncope or Near Syncope

Signs and Symptoms

- Heart Rate: Child > 180/bpm
Infant > 220/bpm
- Pale or Cyanosis
- Diaphoresis
- Tachypnea
- Vomiting
- Hypotension
- Altered Level of Consciousness
- Pulmonary Congestion
- Syncope

Differential

- Heart disease (Congenital)
- Hypothermia/ Hyperthermia
- Hypovolemia or Anemia
- Electrolyte imbalance
- Anxiety/ Pain/ Emotional stress
- Fever/ Infection/ Sepsis
- Hypoxia, Hypoglycemia
- Medication/ Toxin/ Drugs (see HX)
- Pulmonary embolus
- Trauma, Tension Pneumothorax





PEDIATRIC TACHYCARDIA

WIDE COMPLEX (> 0.09 SEC)

Pearls

- **Recommended Exam: Mental Status, Skin, Neck, Lung, Heart, Abdomen, Neuro**
- **Monomorphic QRS:**
All QRS complexes in a single lead are similar in shape.
- **Polymorphic QRS:**
QRS complexes in a single lead will change from complex to complex.
- **Use length-based or weight-based pediatric resuscitation system for medication, equipment, cardioversion, and defibrillation guidance. Pediatric paddles should be used in children < 10 kg.**
- **Rhythm should be interpreted in the context of symptoms and pharmacological or electrical treatment given only when symptomatic, otherwise monitor and reassess.**
- **12-Lead ECG:**
12-Lead ECG is not necessary to diagnose and treat arrhythmia. A single lead ECG is often all that is needed.
Obtain 12-Lead when patient is stable and/ or following a rhythm conversion.
When administering adenosine, obtaining a continuous 12-Lead can be helpful later to physicians.
- **Unstable condition:**
Condition which acutely impairs vital organ function and cardiac arrest may be imminent.
If at any point patient becomes unstable move to unstable arm in algorithm
- **Document all rhythm changes with monitor strips and obtain monitor strips with each therapeutic intervention.**
- **Serious Signs and Symptoms:**
Respiratory distress/ failure.
Signs of shock/ poor perfusion with or without hypotension.
AMS
Sudden collapse with rapid, weak pulse
- **Serious Signs and Symptoms:**
Respiratory distress/ failure.
Signs of shock/ poor perfusion with or without hypotension.
AMS
Sudden collapse with rapid, weak pulse
- **Wide Complex Tachycardia (≥ 0.09 seconds):**
SVT with aberrancy.
VT: Uncommon in children. Rates may vary from near normal to > 200/ minute.
Most children with VT have underlying heart disease / cardiac surgery/ long QT syndrome/ cardiomyopathy.
Amiodarone 5 mg / kg over 20 – 60 minutes or Procainamide 15 mg / kg over 30 – 60 minutes IV / IO are recommended agents. They should not be administered together. Consultation with Medical Control is advised when these agents are considered.
- **Torsade's de Pointes/ Polymorphic (multiple shaped) Tachycardia:**
Rate is typically 150 to 250 beats/ minute.
Associated with long QT syndrome, hypomagnesaemia, hypokalemia, many cardiac drugs.
May quickly deteriorate to VT.
Separating the child from the caregiver may worsen the child's clinical condition.
- **Monitor for respiratory depression and hypotension associated if Diazepam, Lorazepam, or Midazolam is used.**
- **Continuous pulse oximetry is required for all SVT patients if available.**